




Oral implantology Case Presentation

General Data


- Name :
- Gender :
- Age :
- Occupation :
- Date of first visit :



Chief Complaint



Present Illness



Personal history

■ Personal hobbies

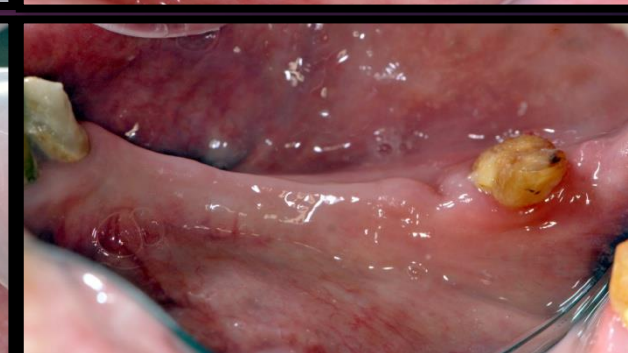
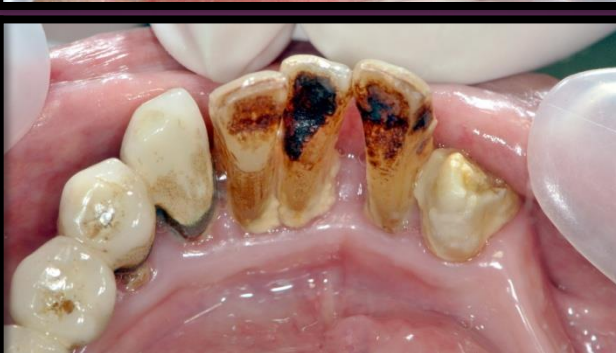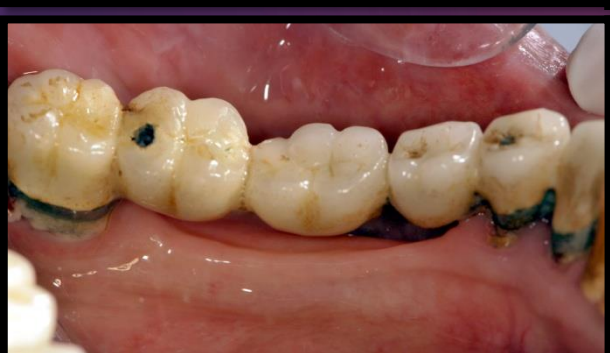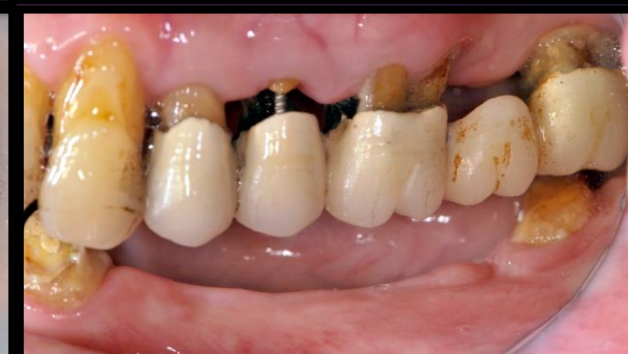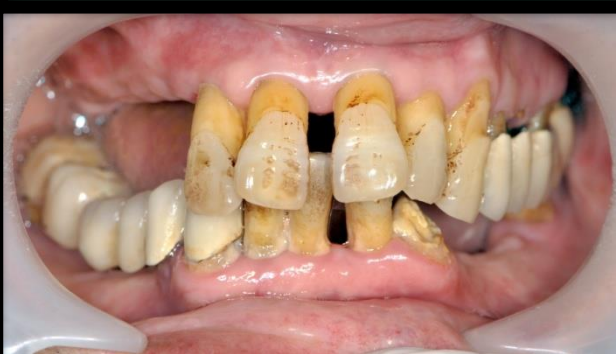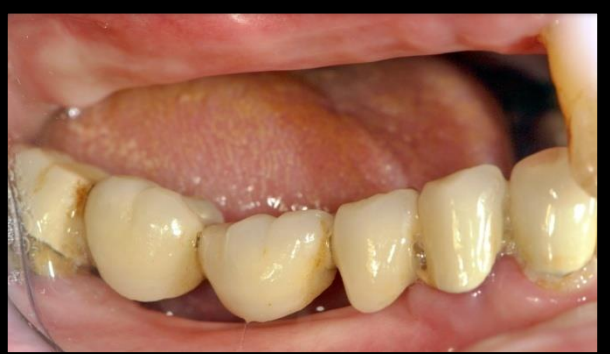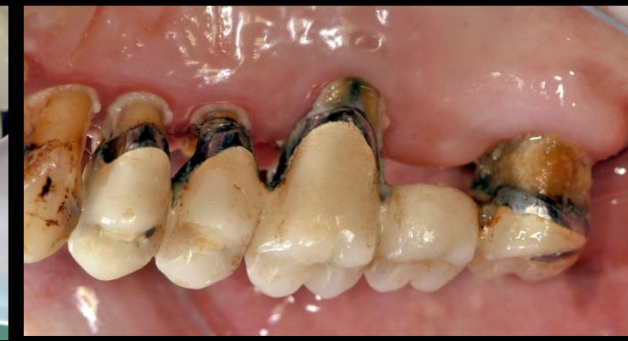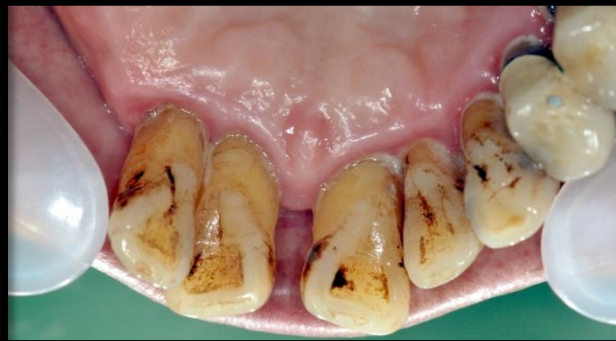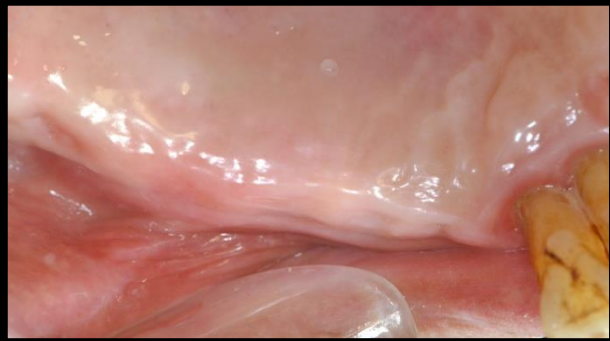
- Smoking (-)
- Alcohol (—)
- Betel quid (—)
- Drug abuse (—)
- Bruxism (-)

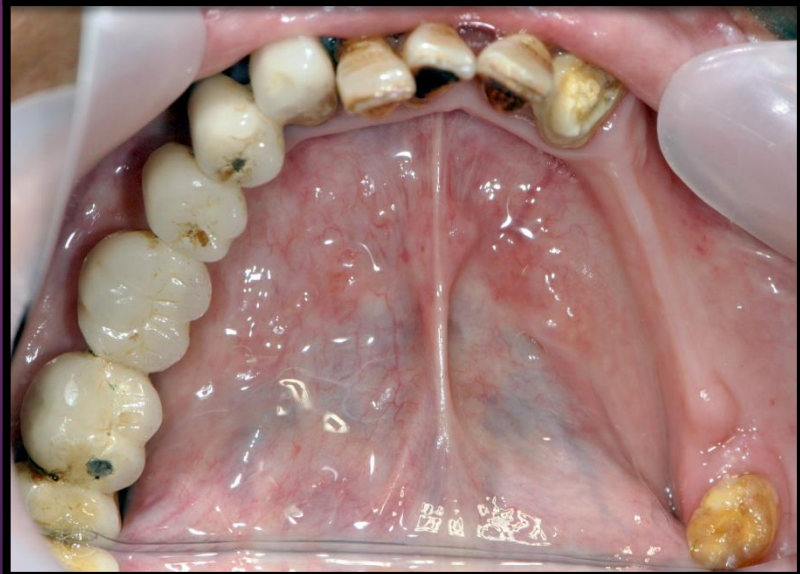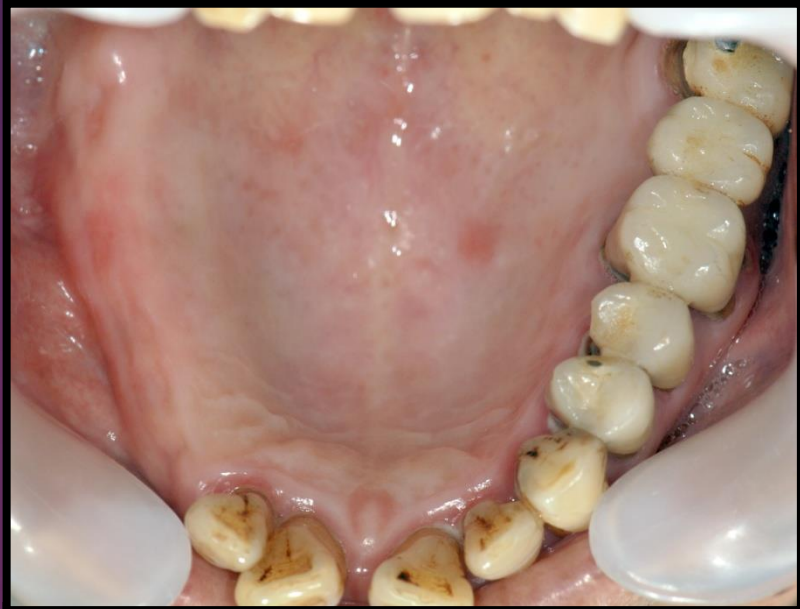Past medical history

Past dental history



Clinical Assessment

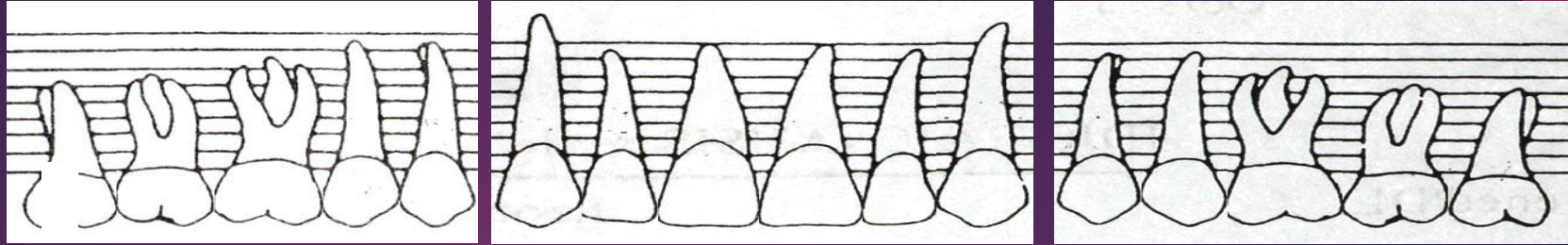




P

18 17 16 15 14 13 12 11 21 22 23 24 25 26 27 28

D



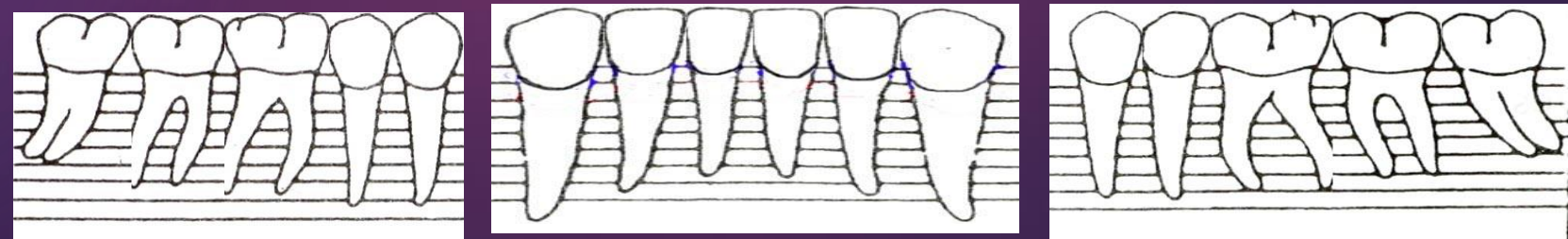
CEJ-GM-F																		133
PD-Facial																		655
PD-Palatal																		744
CEJ-GM-L																		354
Furcation																		
Mobility																		G(I)

Mobility	G(I)																	G(III)
Furcation	G(I)																	
CEJ-GM-L	121																	000
PD-Lingual	667																	434
PD-Facial	577																	433
CEJ-GM-F	201																	000

P

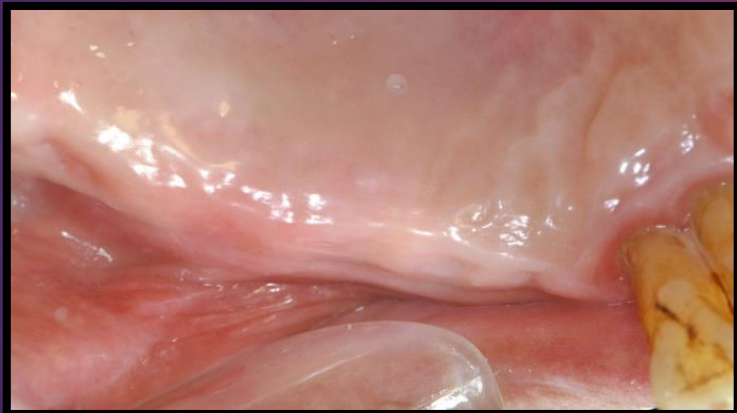
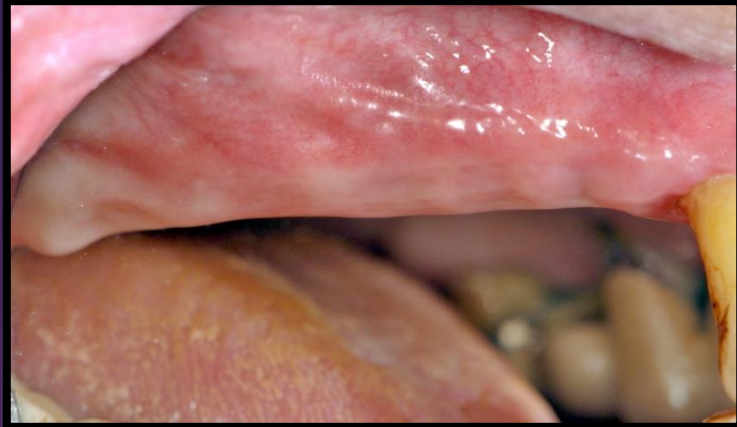48 47 46 45 44 43 42 41 31 32 33 34 35 36 37 38

D



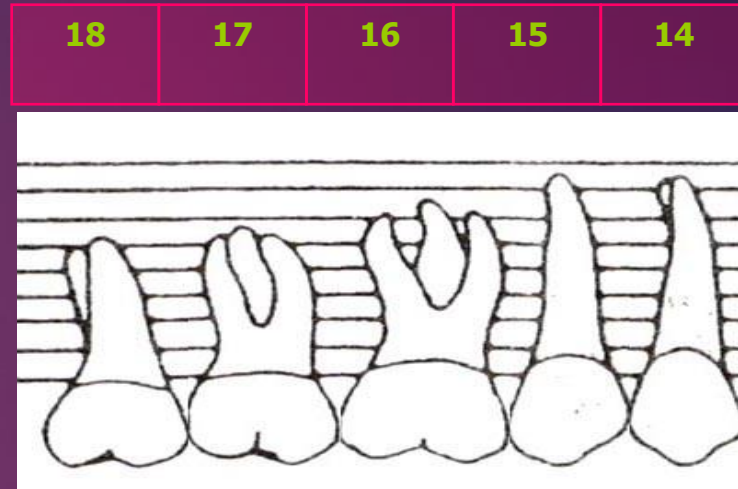
INTRA-ORAL EXAMINATION

Upper Right Sextant



P

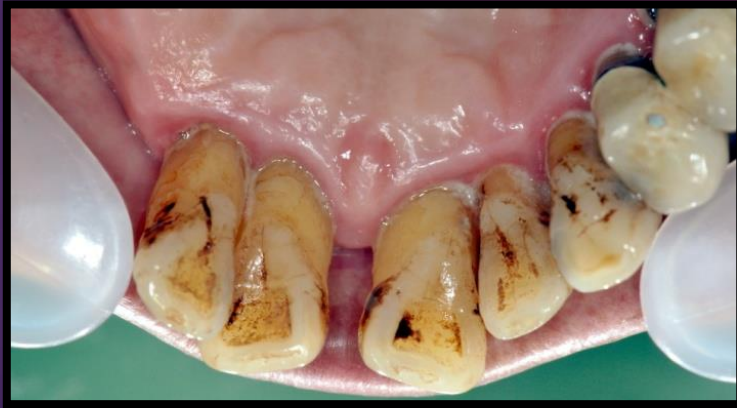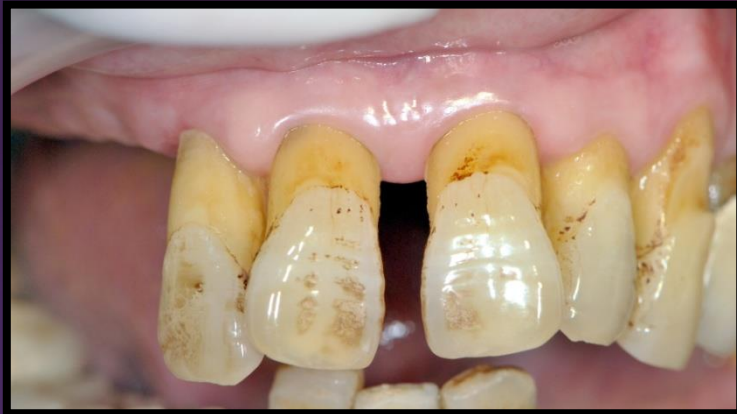D



CEJ-GM-F					
PD-Facial					
PD-Palatal					
CEJ-GM-L					
Furcation					
Mobility					

INTRA-ORAL EXAMINATION

Upper Anterior Sextant



P

13

12

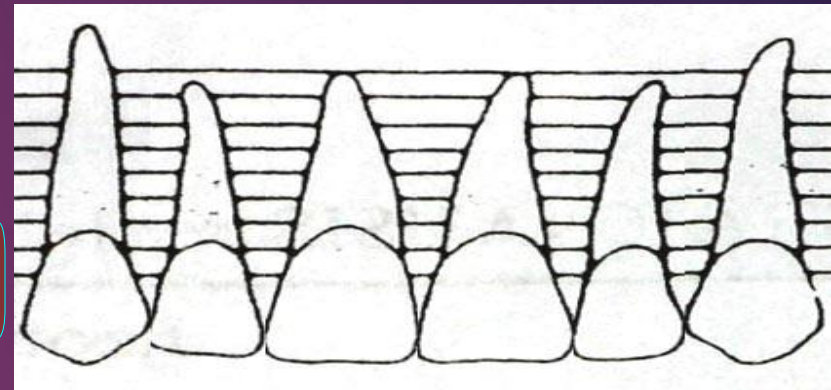
11

21

22

23

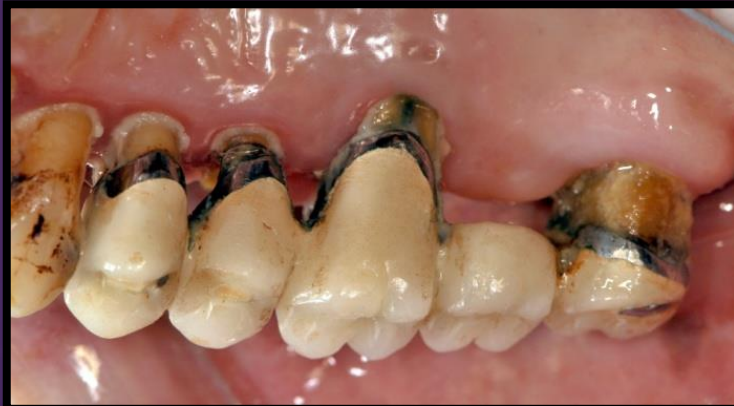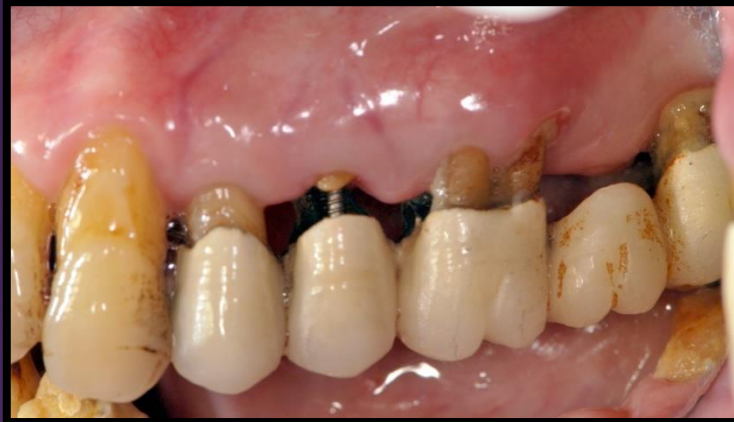D



CEJ-GM-F						
PD-Facial						
PD-Palatal						
CEJ-GM-L						
Furcation						
Mobility						

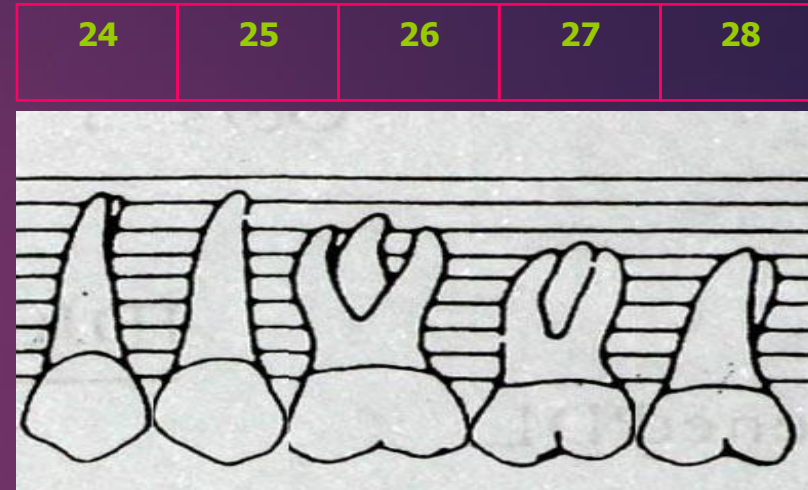
INTRA-ORAL EXAMINATION

Upper Left Sextant



P

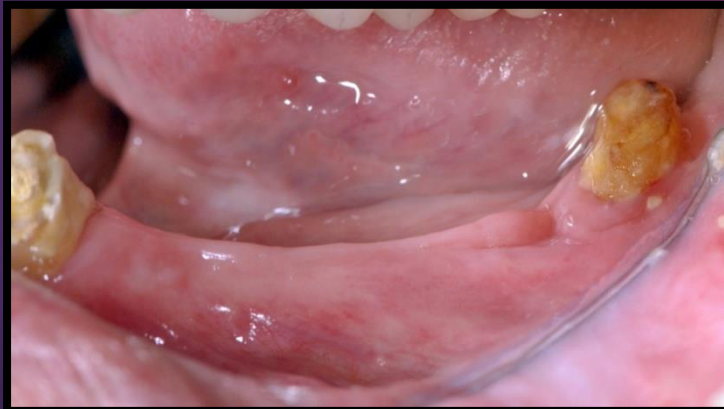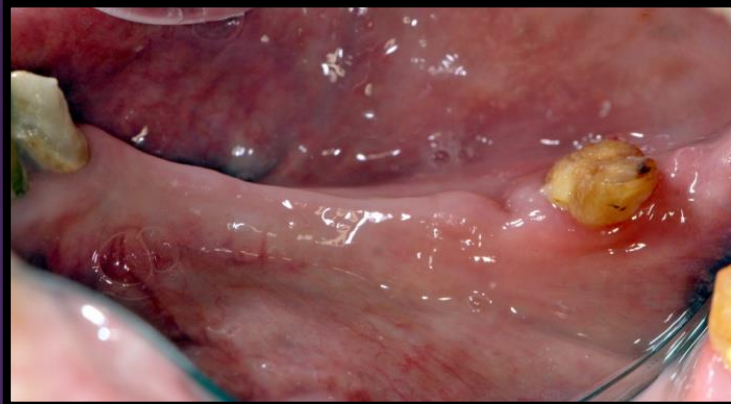
D



	24	25	26	27	28
CEJ-GM-F					
PD-Facial					
PD-Palatal					
CEJ-GM-L					
Furcation					
Mobility					

INTRA-ORAL EXAMINATION

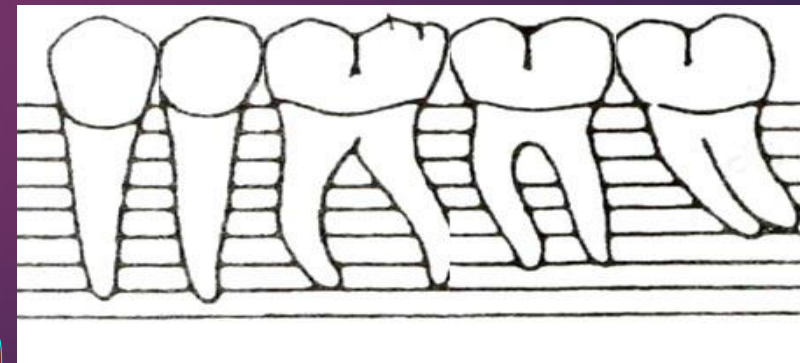
Lower Left Sextant



Mobility					
Furcation					
CEJ-GM-L					
PD-Lingual					
PD-Facial					
CEJ-GM-F					

P

D



34

35

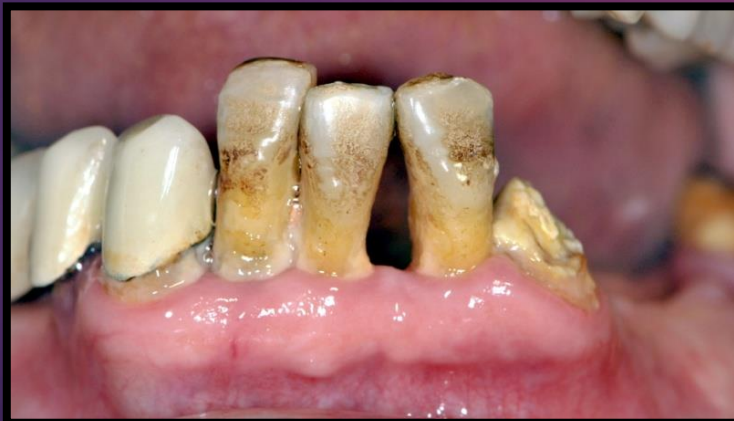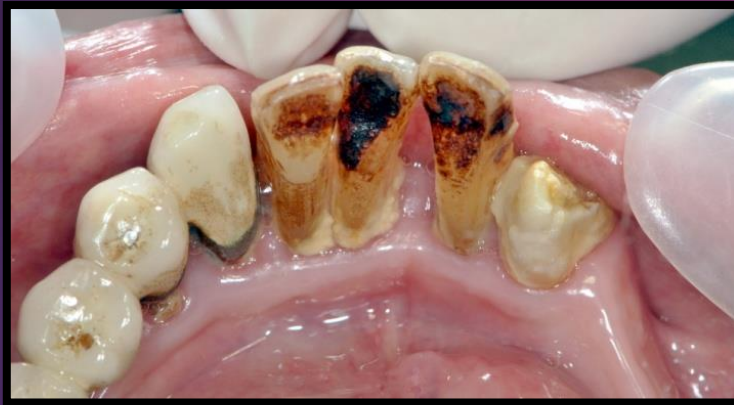36

37

38

INTRA-ORAL EXAMINATION

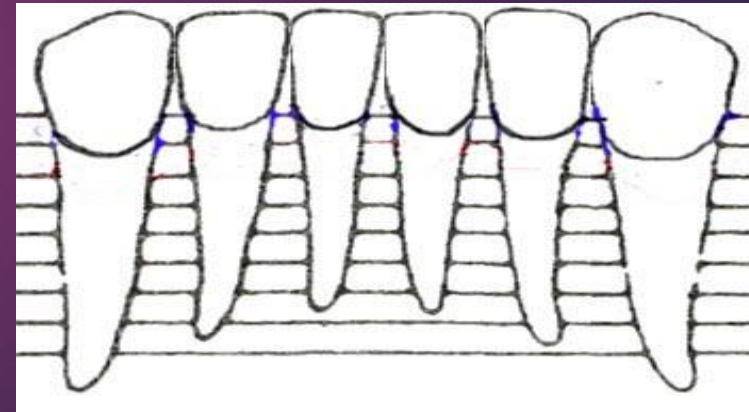
Lower Anterior Sextant



Mobility						
Furcation						
CEJ-GM-L						
PD-Lingual						
PD-Facial						
CEJ-GM-F						

P

D



43

42

41

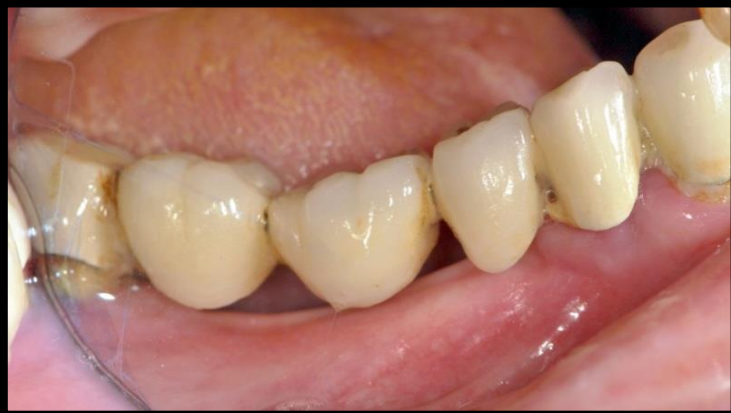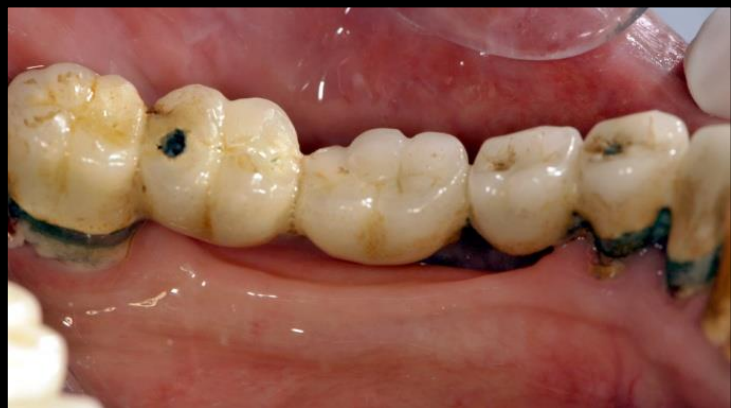31

32

33

INTRA-ORAL EXAMINATION

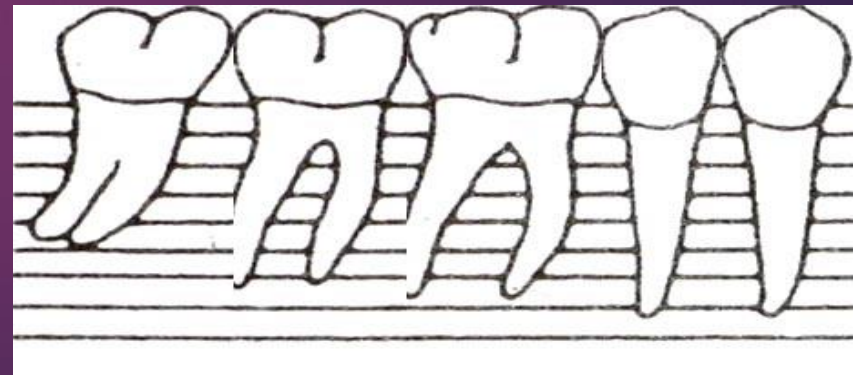
Lower Right Sextant



Mobility					
Furcation					
CEJ-GM-L					
PD-Lingual					
PD-Facial					
CEJ-GM-F					

P

D



48

47

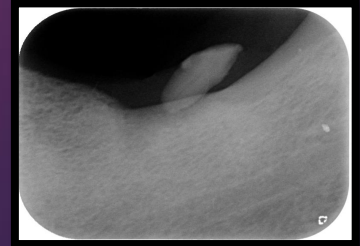
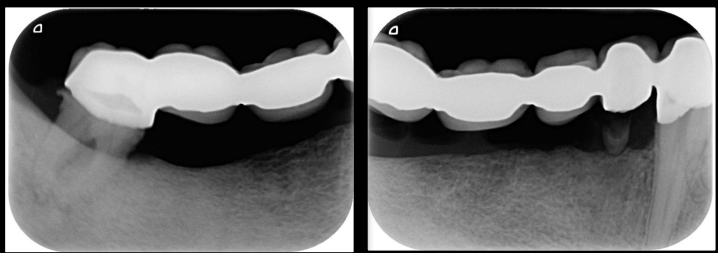
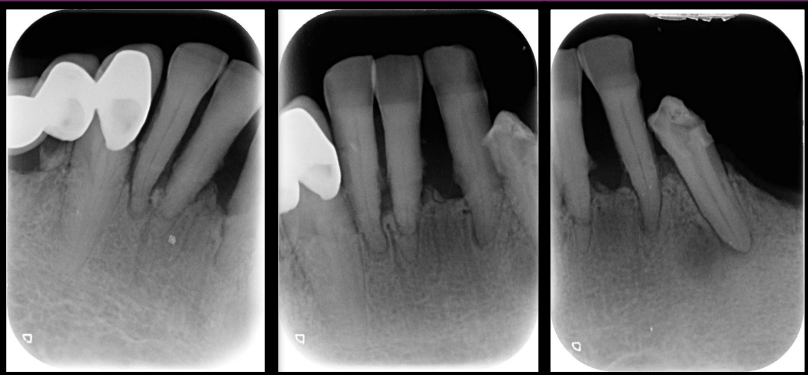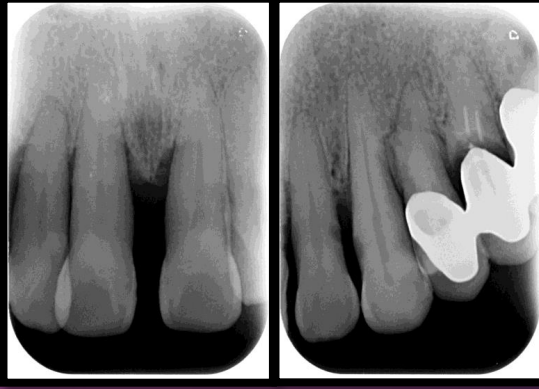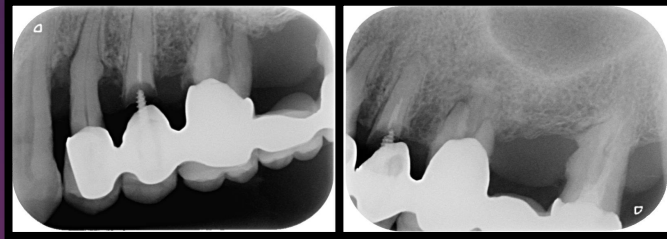

46

45

44



Radiographic Examination



INTRA-ORAL EXAMINATION

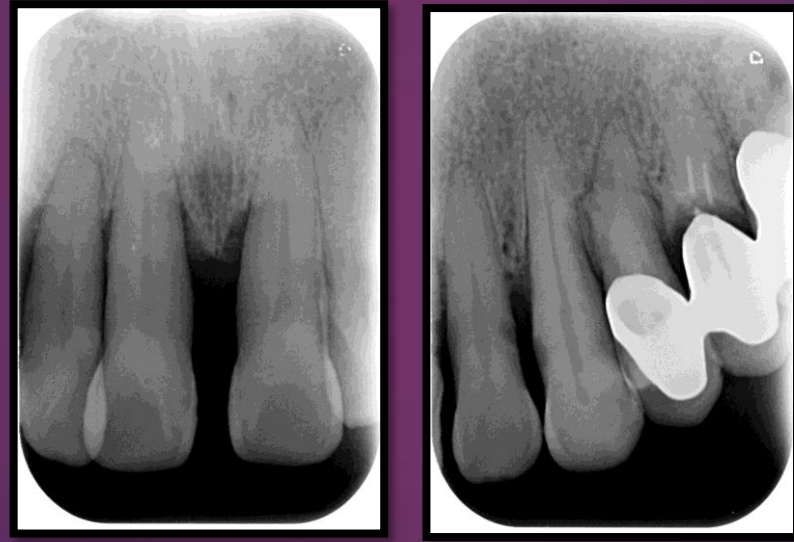Upper Right Sextant

Missing :

- #13,14,15,16,17,18.

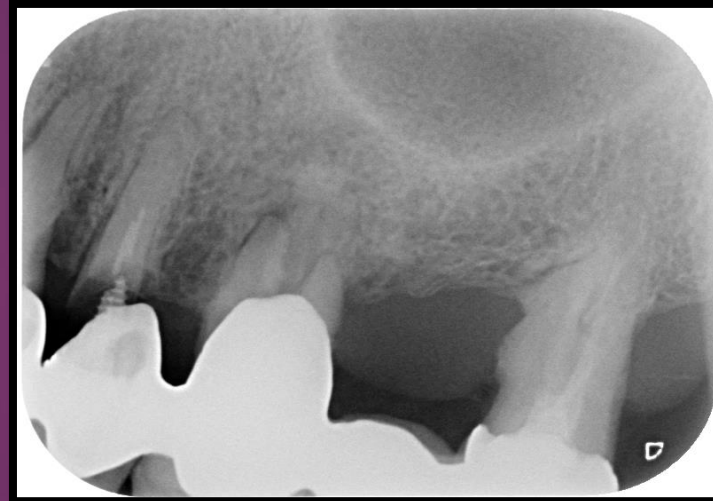
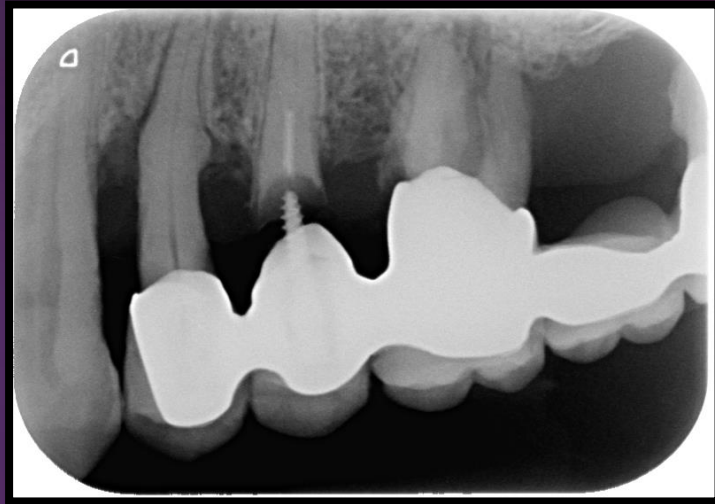INTRA-ORAL EXAMINATION

Upper Anterior Sextant



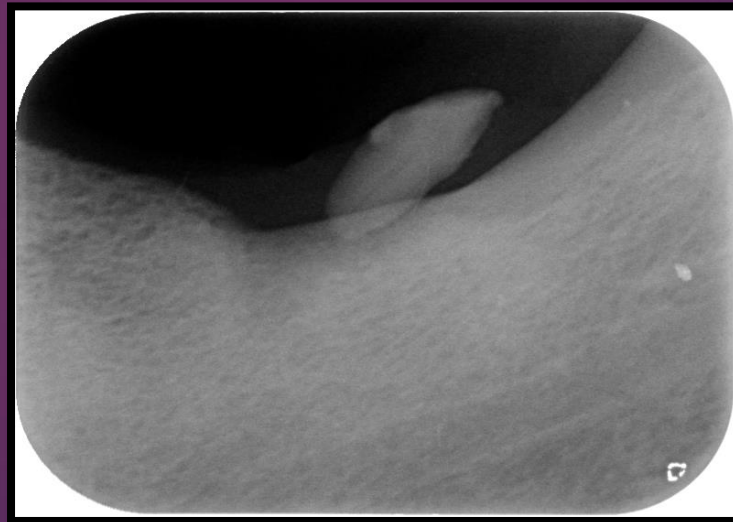
INTRA-ORAL EXAMINATION

Upper Left Sextant



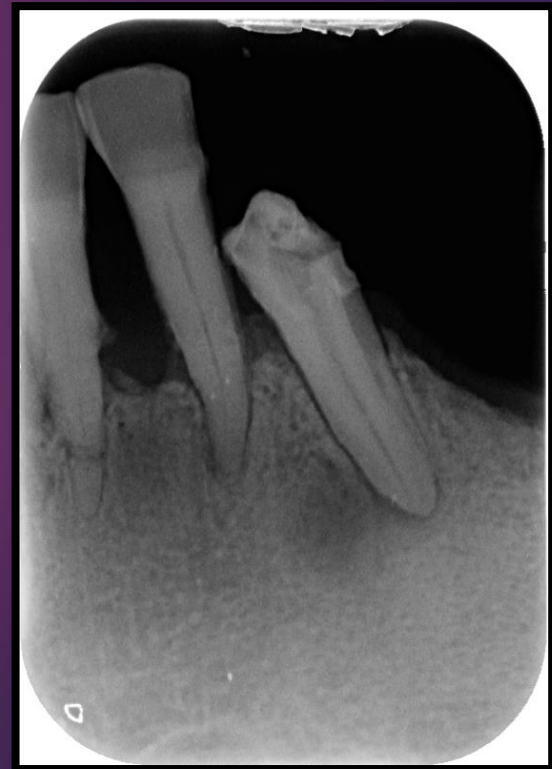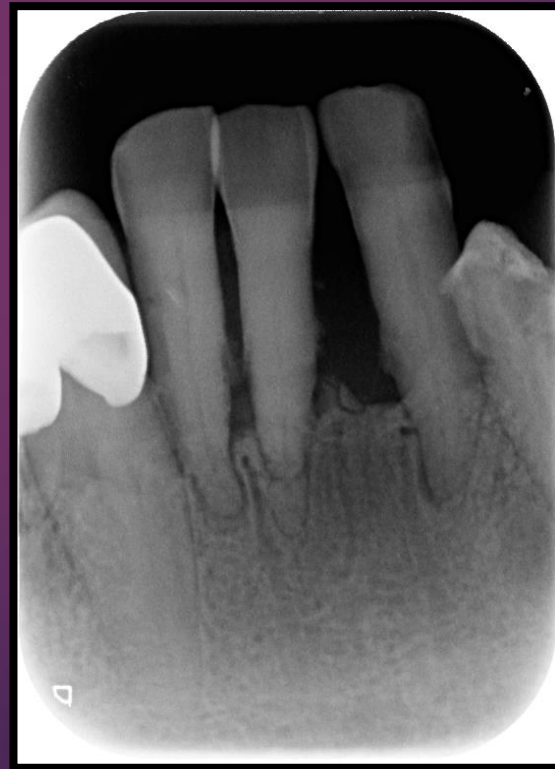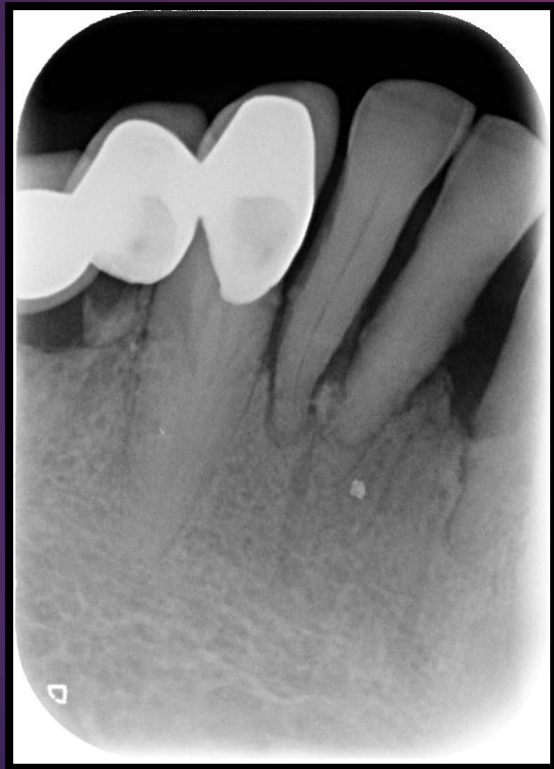INTRA-ORAL EXAMINATION

Lower Left Sextant



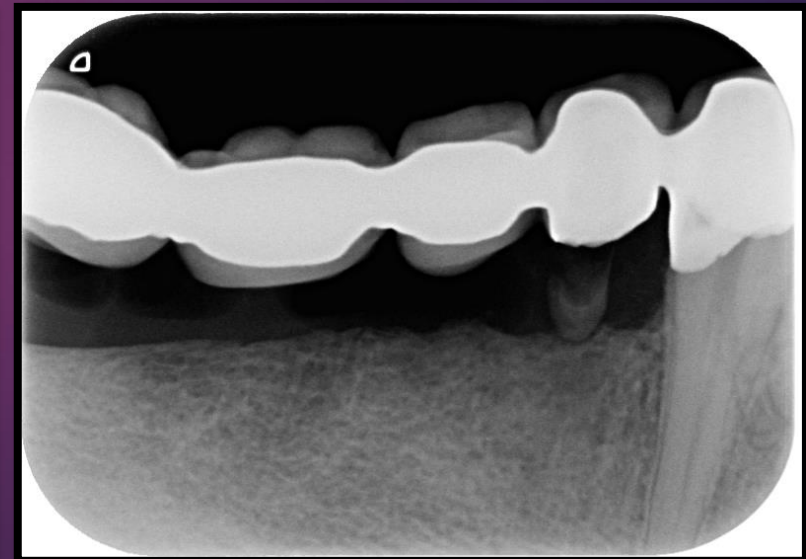
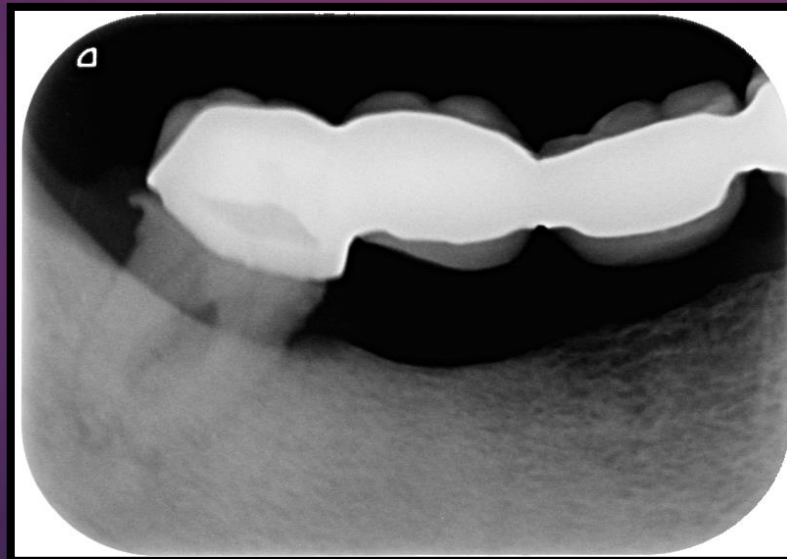
INTRA-ORAL EXAMINATION

Lower Anterior Sextant




INTRA-ORAL EXAMINATION

Lower Right Sextant




CBCT Findings




Occlusal analysis

- ▶ Type of occlusion.
- ▶ Occlusion scheme.
- ▶ Working contacts.
- ▶ Non-Working contacts.
- ▶ Fremitus


Etiologic factors




Problem List




Diagnosis/prognosis/ treatment plan




Prosthetic treatment plan




Extraction/ Socket management




Stage I implant Placement



Stage II implant Surgery



Extraction/ Early implant placement




Extraction/ Immediate implant
placement/ Immediate
provisionalization/ immediate loading

Implant restoration

- ▶ Provisional restoration
- ▶ Final restoration

Maintenance Treatment



THANK YOU